



Patient

NHS No

D.O.B.

Patient Ref

Reason

Angioplasty iliac, Stent

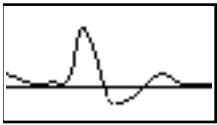
Outcome

Occlusion, Calcified, Bowel gas, Poor images, patient habitus, Stenosis Severe

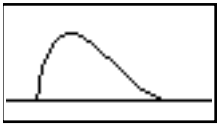
Right

200

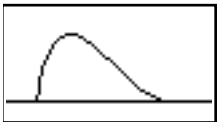
1.00



Good



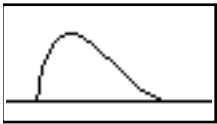
Reduced



Reduced

130

0.65



Reduced

Brachial

Common Femoral

High Thigh

Low Thigh

Popliteal

High Calf

Peroneal

Anterior Tibial

Posterior Tibial

Dorsalis Pedis

Toe Pressure

Post Exercise

Left

Good

turbulent

Reduced

120

0.60

Reduced

Notes

BILATERAL LOWER LIMB ARTERIAL DUPLEX ASSESSMENT

All measurements are proximal to the medial malleolus (MM)

Abdominal aorta was very challenging to visualise due to bowel gas and depth. Where seen, appears patent with good triphasic waveforms PSV 61cm/s. The abdominal aorta appears of normal calibre (maximum LS= 2.0cm).

Assessed by

Lukasz Koprowski

Checked by



Patient

NHS No

D.O.B.

Patient Ref

RIGHT

CIA: Very poorly visualised due to overlying bowel gas and depth. Stent identified which is patent with good monophasic waveforms PSV 163cm/s.

EIA: Unable to visualise the proximal-mid vessel due to overlying bowel gas and vessel depth therefore, unable to comment on patency. Distal EIA is patent with moderate dense diffuse calcified disease; slightly turbulent monophasic waveforms PSV 214cm/s.

CFA: Poorly visualised due to scar tissue. Patent where seen with good triphasic waveforms PSV 108cm/s.

PFA: Moderate dense calcified disease, turbulent biphasic waveforms PSV 130cm/s.

SFA: Remains occluded from the origin. Flow re-forms in the distal thigh (50cmMM) into a moderately diseased vessel; reduced monophasic waveforms PSV 43cm/s.

PopA: Moderate dense diffuse calcified disease, reduced monophasic waveforms PSV 34-37cm/s. TPT is patent, origin of 2 vessel run-off noted.

ATA & PTA: Patent along length but calcified with reduced monophasic waveforms PSV 39-44cm/s at the ankle.

LEFT

CIA: Very poorly visualised due to overlying bowel gas and depth. Stent identified which is patent with good bi/triphasic waveforms PSV 192cm/s.

EIA: Very poorly visualised due to bowel gas and vessel depth. Where seen, patent with moderate dense diffuse calcified disease, turbulent triphasic waveforms PSV 225cm/s.

CFA: Poorly visualised due to scar tissue. Patent where seen with turbulent triphasic waveforms PSV 146cm/s.

PFA: Mild/ moderate dense calcified disease, poorly visualised, turbulent triphasic waveforms PSV 180cm/s.

SFA: Remains occluded from the origin. Flow re-forms in the distal thigh (48cmMM) into a moderately diseased vessel; reduced monophasic waveforms PSV 52cm/s.

PopA: Proximal vessel appears patent, reduced monophasic waveforms, PSV 36cm/s. A focal (~0.8cm), severe area of dense and calcified disease noted at mid vessel, with velocities increasing to 186cm/s (turbulent monophasic). Distal vessel appears to be patent, reduced monophasic waveforms, PSV 62cm/s.

TPT is patent, origin of 2 vessel run-off noted.

ATA & PTA: Patent along length but calcified with reduced monophasic waveforms PSV 52-62cm/s at the ankle.

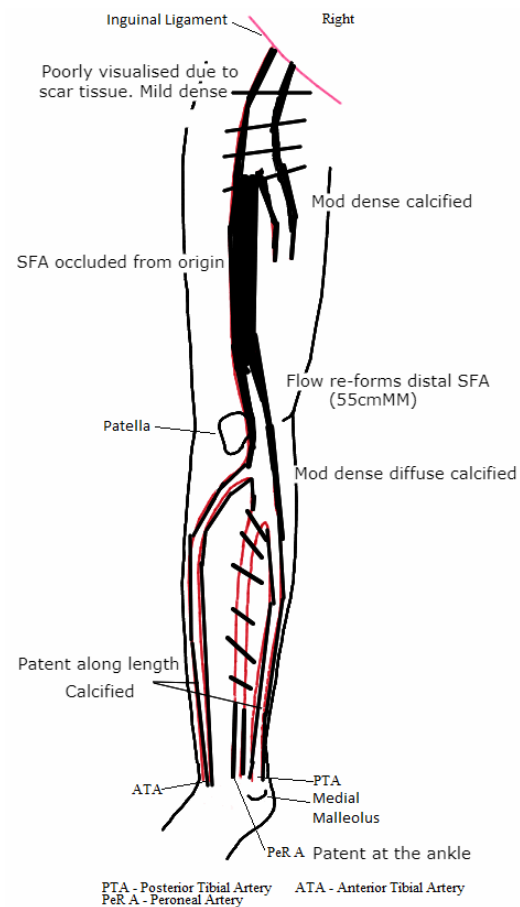
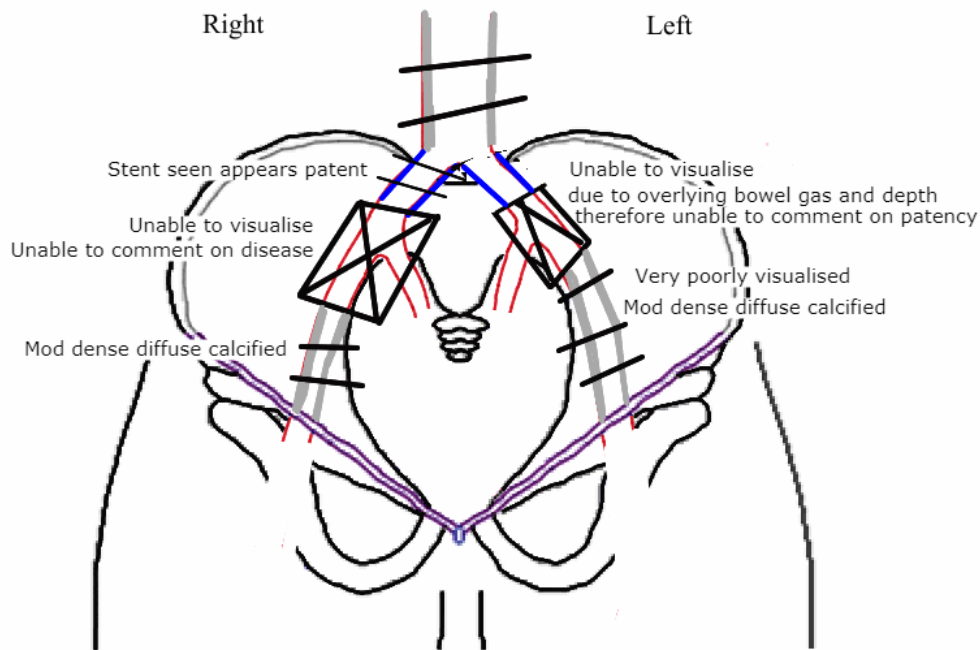
Bilateral, resting ABPIs are reduced (left slightly more than right).

Patient

NHS No

D.O.B.

Patient Ref



Assessed by

Lukasz Koprowski

Checked by

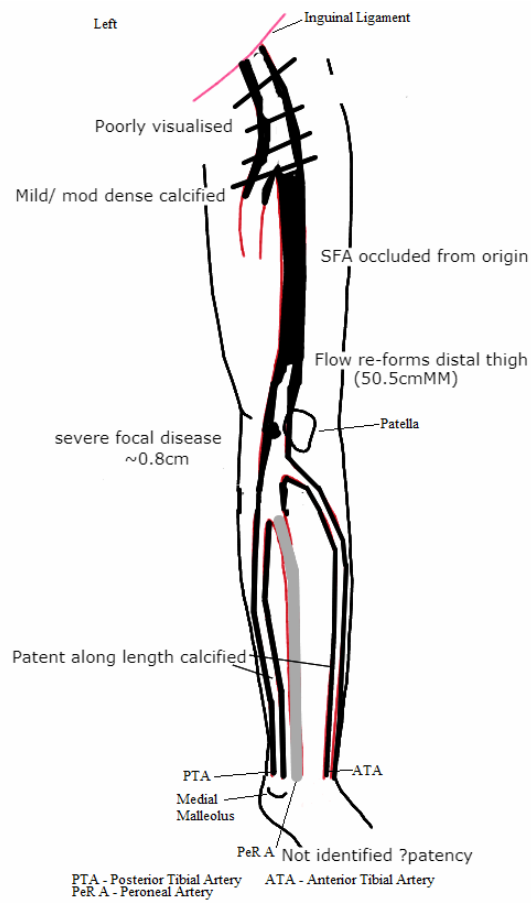


Patient

NHS No

D.O.B.

Patient Ref



Assessed by

Lukasz Koprowski

Checked by